

Quantitative Intramyocardial M-Mode DTI Analysis

M. J. Ledesma-Carbayo^a, N. Malpica^{a,c}, M. Desco^b, J.C. Antoranz^c, A. Santos^a, P. Marcos-Alberca^b, M.A. García-Fernández^b

^aETSI Telecomunicación, Universidad Politécnica de Madrid, 28040 Madrid, Spain.

^bHospital G. U. "Gregorio Marañón", C/ Dr. Esquerdo 46, 28007 Madrid, Spain.

^cFacultad de Ciencias, UNED, Apdo. 60.141, 28080-Madrid, Spain.

andres@die.upm.es

Abstract. *A quantification methodology is proposed for the analysis of DTI M-mode images. After an enhancement stage, the cardiac wall is divided into several layers from which time curves and parameters are computed. A clinical study has been carried out, comparing normal and ischemic patients, in order to characterise the most relevant parameters that assess the intramyocardial left ventricle function. Results show that cross correlation and Fourier analysis may constitute a sensitive test for intramyocardial dysfunction during ischemia.*

Keywords. Doppler Tissue Imaging, quantification methods, ischemia, echocardiography.

1. Introduction

Doppler Tissue Imaging (DTI) is an emerging non-invasive ultrasound technique which allows to measure velocities at any point in the ventricular wall during the cardiac cycle. It produces velocity maps, displayed as a colour overlay superimposed to the gray-scale 2D or M-mode image (Yamazaki, 1995)(Desco, 1997).

Several validation studies of the technique have been performed in different sites (Fleming, 1994) (Yamazaki, 1994). Our specific setting was also previously validated with phantom studies (Desco, 1996), showing acceptable values both for precision and accuracy.

Clinical interpretation of the results is not straightforward because of the large amount of information provided. The lack of appropriate tools implies that the studies are only qualitatively assessed. Standard analysis packages commonly include some simple quantification tools: sample volumes may be positioned with a cursor and the velocity value at those points is displayed on the screen. Also spatial or time profiles along a straight line can be obtained with the newest scanners.

However, more sophisticated processing and quantification tools are required in order to properly assess the left ventricular wall dynamics. The wall thickness change during the heart cycle is an indicator of regional contraction, which is reflected in the gradient of velocity between endocardium and epicardium (Fleming, 1994).

In this paper we describe an image postprocessing methodology to quantify DTI images, stressing its possible application to ischemic disease studies, and providing clinical results on the usefulness of the most relevant time analysis parameters.

2. Methods

A quantification program has been implemented extending the methodology proposed by Desco et al. (Desco 1997). The first step is to extract the velocity values from the colour

image through colour decoding. Once we have the velocity information some post processing is necessary to correct one of the main problems in DTI ultrasound techniques, the so-called black spots or black zones. Average cycle calculation is proposed in order to reduce statistical noise. Anatomical regions are then defined by dividing the endocardial wall in several layers and time velocity profiles in the layers are computed. As a final step, a time analysis is performed over the time curves to extract single figures that assess the viability of the cardiac wall.

In the following sections, the analysis steps are described more in detail.

2.1. Colour decoding

Colour Doppler images acquired with most of the current scanners consist of a true colour image or a colour overlay over the greyscale image. The velocity information is coded in the RGB components through a colour table, which is displayed on the screen. Unfortunately even standard image formats such as DICOM do not usually include the look-up table, that must be provided externally or extracted from the image itself.

2.2. Image enhancement.

The existence of black spots -usually small in size- which do not actually correspond to low velocities is a very common artefact in DTI imaging. This effect degrades noticeably the quality of quantitative data and curves drawn from the images. We use a selective median filtering algorithm, which fills these black spots without altering the remaining valid pixels.

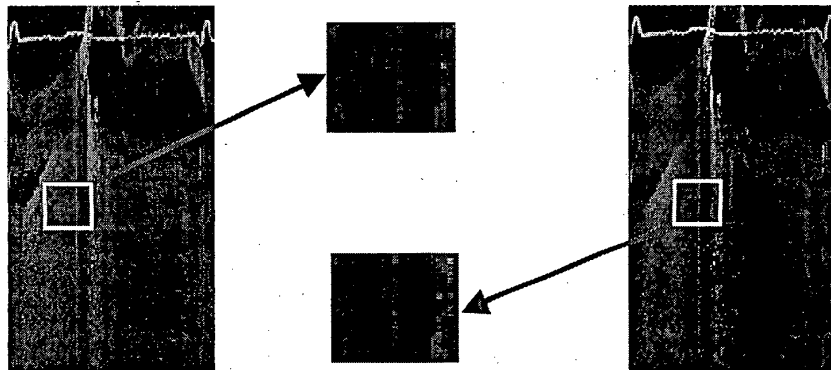


Figure 1. Image enhancement through a selective median filter. *Left:* original image. *Right:* filtered image. Details are shown to see the difference.

The first step is to calculate a median filtered version of the original image (adjustable kernel size, usually 5×5). Then a new image is built with the filtered values replacing the original ones for those points whose value in the initial image is significantly lower than their homologous in the filtered one, thus filtering only the areas affected by the artefact. Figure 1 shows an example of an image before and after the filter is applied.

2.3. Cycle averaging.

Averaging improves the signal-to-noise ratio. The ECG is used as reference to cycles. The time averaging algorithm takes into account only those points that have velocity information above a threshold, thus avoiding the effect of possible black spots.

2.4. Anatomical ROI definition.

To perform the analysis, the cardiac wall is segmented into several layers. The clinician is provided with an assisted interactive drawing tool, based on spline curves, that allows an easy depiction of the cardiac wall borders without much user interactivity. Once the endocardial and epicardial limits are defined, the wall is automatically divided into a number of parallel layers (usually from 3 to 6) for which separate calculations are performed. Some echo scanners provide the feature of acquiring both DTI and greyscale images simultaneously: in this case segmentation can be performed on the greyscale image and then exported to the DTI image. As shown in fig. 2, the anatomic information is much clearer in the greyscale image.

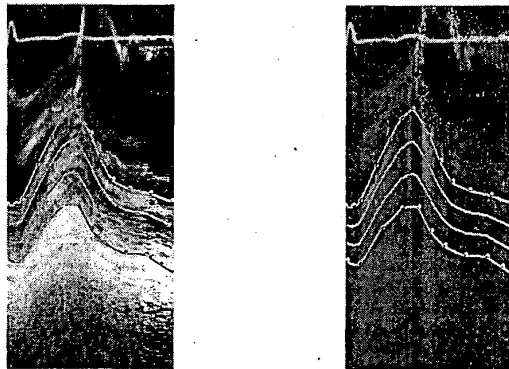


Figure 2. Anatomical ROIs definition. Gray scale image (*left*) is used to define the endocardial and epicardial limits. The cardiac wall is divided into 3 layers to be studied separately. Segmentation is exported to the DTI image (*right*).

2.5. Time curves.

Mean velocity in the different layers and velocity gradient between the endocardium and epicardium, are calculated and graphically represented (Fig 3).

Two different gradient calculation methods have been described in the literature. Fleming *et al.* defined velocity gradient as the unitary spatial rate of change of velocity under the assumption that velocity gradients are linear across the myocardium (Fleming, 1994):

$$\text{Velocity Gradient} = \frac{-dW}{dt} * \frac{1}{W}$$

being W , the wall thickness.

Uematsu *et al.* proposed another calculation method as the difference in myocardial velocity between the endocardium and the epicardium, divided by myocardial wall thickness, (Uematsu, 1995):

$$G = (V_{\text{end}} - V_{\text{epi}}) / W$$

W being the wall thickness, and V_{end} , V_{epi} the true endocardium and epicardium velocities.

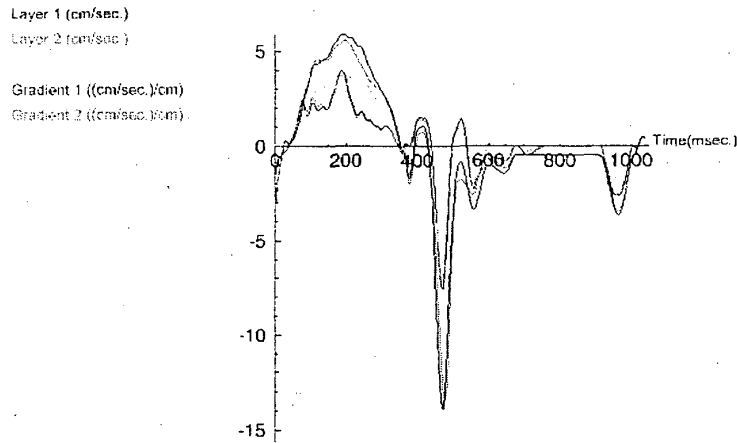


Figure 3. Time course mean velocity curves from three layers of the heart wall. The results from the two described gradient calculation methods are also represented.

2.6. Temporal analysis.

Temporal analysis is performed on the velocity and gradient curves in order to obtain significant single figures to assess the viability of the cardiac wall. The methods proposed are based on Cross-Correlation and Fourier Analysis.

Cross Correlation function is calculated on each curve with respect to the pulse that represents the ideal mechanical systole (fig. 4). Two parameters are extracted: maximum cross correlation coefficient (*CC*) and the time delay (*Delay*), defined as the time shift at which maximum correlation is obtained. Precision of the analysis is checked using the correlation value and its peak width (fig. 4): if cross correlation is too low or the peak too wide data are discarded.

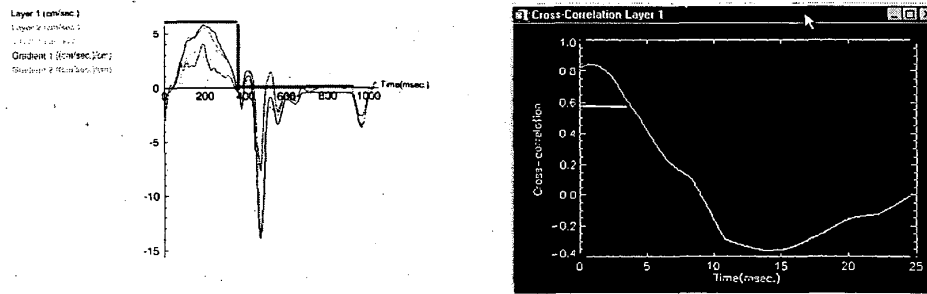


Figure 4. *Left:* representation of the ideal mechanical systole over the curves. *Right:* graphic representation of the cross-correlation results. The peak width is marked as the analysis accuracy indicator.

From the Fourier decomposition two parameters are extracted: first harmonic amplitude (*Amplitude*) and phase (*Phase*) expressed in ms.

Other parameters obtained are: Systolic Average Velocity (*SAV*), Systolic Maximum Velocity (*SMV*), Diastolic Average Velocity (*DAV*), Diastolic Maximum Velocity (*DMV*).

Cross correlation between the inner and outer layers is also computed.

2.7. Experimental Setting

DTI studies were performed on an ACUSON Sequoia scanner. Both colour DTI and greyscale M-mode images were acquired. Images were transferred to a PC by a magnetic optical disk in DICOM format and were analysed with experimental software that integrated all the steps proposed.

A validation study was performed acquiring data from the left ventricle postero-inferior wall in 10 normal volunteers and 10 ischemic patients with abnormal contractility (hipokinesia or akinesia). Velocity and transmural gradient waveforms from three myocardial layers were obtained and analysed with the methodology proposed.

3. Results and Discussion

Image enhancement proved to be effective providing smoother curves. Images themselves appear less noisy as shown in fig. 3. Time averaging process also produced a considerable statistical noise reduction, incrementing quantification accuracy.

Table 1 shows the time analysis results after dividing the wall into three layers. It can be seen that the cross-correlation and the phase parameters show significant differences between normal and ischemic patients in all cases. Maximum systolic and diastolic velocities also decrease significantly in endocardium and mesocardium.

Table 1. Results from the analysis of 10 normal and 10 ischemic patients. Parameters are described in section 2.6. Data as mean value \pm SEM. Asterisk indicates $p \leq 0.05$ (Mann-Whitney)

	Endocardium		Mesocardium		Epicardium	
	Normal	Ischemic	Normal	Ischemic	Normal	Ischemic
CC	0.74\pm0.02	0.80\pm0.01 *	0.75\pm0.02	0.82\pm0.01 *	0.77\pm0.02	0.83\pm0.01 *
<i>Delay</i>	16.82 \pm 9.0	25.50 \pm 8.70	7.88 \pm 3.19	20.64 \pm 6.40	5.92 \pm 1.94	16.93 \pm 5.17
Phase	110.20\pm8.3	147.64\pm12.9 *	106.91\pm11.1	145.23\pm10.2 *	106.74 \pm 12.0	140.01 \pm 9.8
<i>Amplitude</i>	1.44 \pm 0.08	1.33 \pm 0.13	1.46 \pm 0.11	1.30 \pm 0.14	1.04 \pm 0.07	1.13 \pm 0.13
<i>S.A.V.</i>	3.25\pm0.19	2.63\pm0.43 *	3.27 \pm 0.20	2.68 \pm 0.45	2.27 \pm 0.13	2.28 \pm 0.36
<i>S.M.V.</i>	5.70\pm0.25	4.64\pm0.69 *	5.16 \pm 0.28	4.37 \pm 0.65	3.76 \pm 0.23	3.89 \pm 0.53
<i>D.A.V.</i>	-1.79 \pm 0.14	-1.69 \pm 0.17	-1.80 \pm 0.16	-1.70 \pm 0.16	-1.36 \pm 0.12	-1.56 \pm 0.18
<i>D.M.V.</i>	-10.56\pm1.0	-7.53\pm1.37 *	-10.50 \pm 0.63	-6.9 \pm 1.26	-6.25 \pm 0.37	-5.40 \pm 0.78

Temporal analysis of mean velocity in cardiac wall layers seems to provide a good assessment of intramyocardial left ventricle function. Normal patterns in healthy volunteers have been previously characterised by our group (García-Fernández 1997). The results presented here suggest that some parameters (mainly cross correlation and phase) may constitute a sensitive test of intramyocardial dysfunction during ischemia.

References

1. Desco M, Antoranz C, García-Fernández M. (1996) "Quantitative Analysis of Colour-Coded Doppler Tissue Images." In: *Computer Assisted Radiology* ed. by H.U. Lemke

- MWV, K. Inamura and A.G. Farman, CAR'96. Paris: Elsevier Scie., Amsterdam, pp. 1004.
2. Desco M and Antoranz JC (1997a), "Technical Principles of Doppler Tissue Imaging". In: *Doppler Tissue Imaging*. ed. by García-Fernández MA, McGraw-Hill, New York.
 3. Desco M and Antoranz JC, García-Fernández M.A., López J., Puerta P., Barreno P.G. (1997b), Ischemic disease assessment through quantitative Doppler tissue imaging. In: *Computer Assisted Radiology* ed. by H.U. Lemke, M.W. Vannier and K. Inamura, CAR'97. Berlin: Elsevier Scie., Amsterdam, pp. 169-172.
 4. Fleming, A., Xia, X., McDicken, W., Sutherland, G., Fenn, L. (1994) "Myocardial Velocity Gradients Detected by Doppler Imaging System". *British J Radiology* Vol. 67 pp. 679-88.
 5. García-Fernandez, M., Azevedo, J., Guinea, J., et al. (1996) "Time to peak intramiocardial early relaxation velocity of the left ventricular edocardium by color Doppler Tissue Imaging as a new index of regional diastolic ischemic dysfunction." *European Heart Journal*. Vol. 17(Suppl.) pp.566.
 6. García-Fernández M.A., Zamorano J., Azevedo J. (1997), *Doppler Tissue Imaging*, McGraw-Hill, New York.
 7. Uematsu, M., Miyatake K., Tanaka N., Matsuda H., Sano A. Yamakazi N. (1995) Myocardial Velocity Gradient by tissue doppler study. *J of Am Coll Cardiol*, vol. 26, no. 1, pp: 2223.
 8. Yamazaki, N., Mine, Y., Sano, A., et al. (1994) "Analysis of Ventricular Wall Motion Using Color-Coded Tissue Doppler Imaging System". *Japan J Appl Physics* Vol.33, pp. 3141-3146.
 9. Yamazaki, N. (1995) "Principles of Doppler Tissue Velocity Measurement". In: *Atlas of Tissue Doppler Echocardiography (TDE)*. ed. by Erbel R, Nesser H, Drozdz J, Darmstadt: Steinkopff, pp. 9-15.